Bilgi ve Hazırlık İçin

USCAMP'DEN

40 SORULUK ÜCRETSİZ *USMLE* DENEME SINAVI

USCAMP

#since2017

1) A 50-year-old female with a long-standing history of rheumatoid arthritis presents to the rheumatology clinic with worsening joint pain and swelling in her hands and feet. She reports increased morning stiffness lasting more than an hour. On examination, there is synovial thickening and tenderness in multiple joints. Laboratory tests reveal elevated levels of inflammatory markers, including C-reactive protein and erythrocyte sedimentation rate. A diagnosis of active rheumatoid arthritis is made, and the patient is started on disease-modifying antirheumatic drugs. During the process of leukocyte transmigration from the vascular endothelial cells to the extravascular space in the setting of inflammation, which of the following adhesion molecules is most likely to play a crucial role ?

A) Integrin
B) E-selectin
C) PECAM-1
D) ICAM-1
E) Sialyl-Lewis X

2) A 42-year-old male with a history of chronic glaucoma presents to the ophthalmology clinic for a routine follow-up visit. Despite being compliant with his topical medications, the patient's intraocular pressure remains elevated, and he has progressive visual field loss. The ophthalmologist decides to add a new medication to the patient's treatment regimen to further reduce intraocular pressure. The new medication is a potent vesicular transporter blocker, which inhibits the uptake of acetylcholine into synaptic vesicles. In addition to its ocular use, this medication has been studied as a potential therapeutic agent in certain neurological disorders, including Alzheimer's disease. Which of the following agents is most likely to be added to the patient's glaucoma treatment regimen ?

A) Integrin
B) E-selectin
C) PECAM-1
D) ICAM-1
E) Sialyl-Lewis X

3) A 35-year-old male presents to the clinic with complaints of weakness and fatigue. He reports experiencing frequent episodes of low blood sugar levels, especially after overnight fasting. Laboratory investigations reveal the presence of abnormally short branches in the large liver glycogen structures compared to normal. In this case, which of the following structures is likely to have a defect leading to this abnormality ?

A) Glycogen phosphorylase
B) Glucagon receptor
C) Glycogenin
D) Amylo-1,6-glucosidase
E) Amylo-4,6-transferase

4) A 2-year-old child is brought to the pediatrician due to developmental delay and distinctive facial features. Physical examination reveals coarse facial features, corneal clouding, hepatosplenomegaly, and joint stiffness. Laboratory studies show increased urinary excretion of dermatan sulfate and heparan sulfate. Genetic testing confirms the diagnosis of a spesific syndrome. Which of the following enzymes is deficient in this syndrome ?

A) Alpha-L-iduronidase
B) Iduronate-2- sulfatase
B) Beta-glucocerebrosidase
C) Alpha-galactosidase A
D) Sphingomyelinase

5) A 45-year-old obese male presents to his primary care physician with complaints of recurrent episodes of abdominal pain, which seem to be triggered by large, fatty meals. The pain is localized to the upper abdomen and is associated with bloating and flatulence. Laboratory investigations reveal elevated levels of triglycerides (>1000 mg/dL) and normal levels of total cholesterol. Fasting blood glucose levels are within the normal range. Which of the following is the primary defect in this disorder ?

A) Deficiency of lipoprotein lipase
B) Overproduction of VLDL
C) Impaired hepatic uptake of remnants
D) Deficiency of hepatic triglyceride lipase
E) Overproduction of apolipoprotein C-II

6) A 32-year-old male with a history of type 1 diabetes mellitus presents to the emergency department with symptoms of nausea, vomiting, and abdominal pain. On physical examination, the patient appears lethargic, and his breath has a distinctive odor. Laboratory tests reveal elevated blood glucose levels, ketonuria, and an increased anion gap. The presence of a specific odor in the patient's breath is primarily attributed to which of the following compounds ?

A) Acetoacetate
B) β-hydroxybutyrate
C) Acetone
D) Acetyl-CoA
E) CO2

7) A 60-year-old male presents to the emergency department with severe retrosternal chest pain that has been ongoing for the past 2 hours. An electrocardiogram shows ST-segment elevation in leads II, III, and aVF. The patient is promptly taken for cardiac catheterization, where a complete occlusion of the right coronary artery is identified and successfully treated with percutaneous coronary intervention. Ten days later, the patient passes away due to complications unrelated to the initial MI. Autopsy is performed and gross examination of the heart reveals a well-demarcated, depressed, yellow-tan area in the posterior wall of the left ventricle. Microscopic examination of this area shows coagulative necrosis, a dense infiltrate of neutrophils, and granulation tissue. Which of the following is the most appropriate term to describe this finding ?

A) Acute inflammation
B) Subacute inflammation
C) Chronic inflammation
D) Organization
E) Scar formation

8) A 65-year-old female presents to the emergency department with progressively worsening shortness of breath, palpitations, and fatigue for the past few months. She reports increasing difficulty performing routine activities such as climbing stairs and feels exhausted after minimal exertion. She has a history of rheumatic fever during childhood but was never treated adequately. On examination, she appears pale, and her vital signs reveal a heart rate of 110 bpm, blood pressure of 130/80 mmHg, respiratory rate of 22 breaths per minute, and oxygen saturation of 92% on room air. Auscultation reveals an opening snap followed by a diastolic rumble at the apex. A mid-diastolic rumble is also heard at the left lower sternal border. Jugular venous distention is noted. Which of the following is most likely to be seen on echocardiography ?

A) Enlarged left ventricular cavity
B) Enlarged right ventricular cavity
C) Left atrial enlargement
D) Left ventricular wall thickening
E) Right ventricular wall thickening

9) A 52-year-old male presents to the cardiology clinic with complaints of increasing fatigue, dyspnea on exertion, and peripheral edema for the past several months. He reports a history of alcohol abuse for the past 10 years and denies any history of viral illnesses or familial heart disease. On physical examination, the patient appears tired and appears to be in respiratory distress. Blood pressure is 110/70 mmHg, heart rate is 100 beats per minute and irregularly irregular, and respiratory rate is 24 breaths per minute. Jugular venous distention is noted at a 30-degree angle. Cardiac auscultation reveals a regular S1 and a low-pitched S3 gallop sound. A holosystolic murmur is heard at the apex radiating to the axilla. Pulmonary examination shows bilateral crackles in the lung bases. Abdominal examination reveals hepatomegaly and mild ascites. An echocardiogram reveals a decreased systolic function and global hypokinesis. Which of the following findings is most likely to be present on an echocardiogram additionally ?

	Left atrial cavity size	Left ventricular cavity size	Left ventricular wall thickness	Left ventricular
A)	Dilated	Not dilated	Normal	Normal
B)	Dilated	Dilated	Normal	Impaired
C)	Dilated	Not dilated	Increased	Impaired
D)	Not dilated	Dilated	Increased	Impaired
E)	Not dilated	Dilated	Increased	Normal

10) A 3,500-gram male newborn is delivered vaginally. At 20 hours postnatal, the infant is noted to have cyanosis and tachypnea. Transcutaneous oxygen saturation is measured at 85%. On physical examination, the heart rate is 165 beats per minute, femoral pulses are palpable, S1-S2 sounds are normal, and no murmurs are appreciated. The electrocardiogram (EKG) reveals a right-axis deviation within normal limits for a newborn. Chest radiography demonstrates an "upside-down egg" appearance of the cardiac silhouette, and pulmonary vascularity appears normal. Which of the following is the most likely mechanism that is responsible for this clinical presentation of this patient ?

A) Obstructive type of total anomalous pulmonary venous return
B) Displacement of tricuspid valve leaflets downward into right venricule
C) Anterosuperior displacement of the infundibular septum
D) Separation of the systemic and pulmonary circulations
E) Absence of tricuspid valve

11) A 38-year-old woman presents to her primary care physician with complaints of fatigue, weight gain, and constipation over the past several months. She reports feeling cold all the time and notices increased dryness of her skin and hair. On physical examination, her blood pressure is 120/80 mmHg, her heart rate is 68 beats per minute, and she has a diffuse, non-tender enlargement of the thyroid gland. Laboratory tests reveal an elevated thyroid-stimulating hormone level of 15 mIU/L (normal range: 0.3-5.0 mIU/L) and a decreased free thyroxine level of 0.5 ng/dL (normal range: 0.8-1.8 ng/dL). Thyroid peroxidase antibody and thyroglobulin antibody levels are significantly elevated. Given the clinical presentation and the biopsy findings, which of the following is the most likely histological characteristic that would be expected in the thyroid gland tissue sample taken from this patient ?

A) Tall, crowded follicular epithelial cells
B) Lymphoid aggregates with germinal centers
C) Focal patches of hyperfunctioning follicular cells
D) Concentric lamellated calcified structures
E) Granulomatous inflammation

12) A 25-year-old male patient presents with a history of episodic sweating, headaches, and palpitations that have been occurring for several months. He suspects that these symptoms may be related to stress. Upon further inquiry, the patient reveals that about 6 months ago, he underwent surgery for a fracture, during which the anesthesiologist noticed fluctuations in his blood pressure and recommended evaluation for hypertension. On physical examination, his height is 180 cm, weight is 72 kg, pulse rate is 80 beats per minute, and arterial blood pressure is 135/80 mmHg. Laboratory tests, including blood glucose and thyroid function tests, are within normal limits. In the evaluation of this patient, which of the following markers could be used ?

A) Desmin
B) Synaptophysin
C) Cytokeratin
D) GFAP
E) S-100
F) Vimentin
G) TRAP

13) A 67-year-old male patient with a history of small-cell lung cancer presents to the emergency department with a one-week history of nausea, headache, and increasing confusion. His family reports that he has been drinking excessive amounts of water and urinating frequently. On physical examination, the patient is found to have mild peripheral edema. Laboratory investigations reveal hyponatremia with a sodium level of 125 mEq/L. The patient's serum osmolality is decreased, while urine osmolality is increased.
Which of the following signaling pathways does the hormone causing this condition use ?

A) cAMP
B) cGMP
C) IP3
D) Intracellular receptor
E) Receptor tyrosine kinase
F) Nonreceptor tyrosine kinase

14) A 65-year-old patient with type 2 diabetes mellitus is scheduled for a follow-up visit with their primary care physician. The patient has been recently started on a new medication that inhibit the DPP-4 enzyme for glycemic control. Which of the following is a potential side effect of this medication ?

A) Peripheral edema due to fluid retention
B) Weight gain resulting from increased appetite
C) Musculoskeletal pain related to altered bone metabolism
D) Respiratory and urinary tract infections
E) Hypoglycemia due to increased insulin secretion

15) A 48-year-old male with a past medical history of hyperlipidemia and smoking presents to the emergency department with acute chest pain and shortness of breath. The pain started approximately 2 hours ago and has been constant in intensity since then. He also reports feeling lightheaded and nauseous. On examination, his blood pressure is 160/90 mmHg, heart rate 100 beats per minute, and respiratory rate 22 breaths per minute. Cardiac auscultation reveals a regular rhythm without murmurs. An electrocardiogram shows ST-segment elevation in leads V2 to V4 and ST-segment depression in leads II, III, and aVF. Cardiac enzymes are elevated. In the patient, atherosclerosis is detected in the artery that supplies the apex of the heart during the coronary angiography. which of the following arteries is most likely affected, as evidenced by atherosclerosis observed in the coronary angiography ?

A) Sinus node artery
B) Right marginal artery
C) Posterior descending artery
D) Anterior descending artery
E) Circumflex artery

16) A 52-year-old male patient with a history of hypertriglyceridemia presents to his primary care physician with complaints of recurrent episodes of right upper quadrant abdominal pain. He describes the pain as colicky and aggravated by fatty meals. The patient has a history of hypertriglyceridemia and has been taking a medication to lower her triglyceride levels. Physical examination reveals tenderness upon palpation of the right upper abdomen. Laboratory investigations show elevated triglyceride levels, as well as the presence of cholesterol gallstones on abdominal ultrasound. Which of the following mechanisms best explains the increased risk of cholesterol gallstone formation ?

A) Inhibition of HMG-CoA reductase
B) Inhibition of HMG-CoA synthetae
C) Inhibition of squalene synthetae
D) Inhibition of cholesterol 7α-hydroxylase
E) Inactivation of LDL-receptor degradation

17) A 5-year-old male child presents to the pediatric oncology clinic with a complaint of rapidly increasing abdominal distension over the past few weeks. His parents noticed that his abdomen appeared larger and firmer than usual. The child's medical history is unremarkable, and there are no significant findings upon physical examination apart from the distended abdomen. Further evaluation through imaging reveals the presence of widespread ascites and a palpable mass in the ileocecal region. Laboratory analysis of the ascitic fluid shows the presence of vacuolated cytoplasmic immature cells. To determine the lineage of these cells, immunophenotyping is performed, which confirms that they carry a B-cell phenotype. Based on the clinical and laboratory findings, which of the following mutations is most likely to be detected in this patient?

A) Cyclin D1
B) MYC
C) t(14;18)
D) BRAF
E) t(11;14)

18) A 12-old girl presents to her primary care physician with weakness, fatigue, and a feeling of fullness in the left upper quadrant. She expresses that she has always been sluggish and pale since childhood. She states that one of her siblings also died of severe anemia in her childhood. On physical examination, pallor and spleen 1 cm are palpable. In his laboratory, hemoglobin 10 gr/dl, MCV 64, RDW, MCHC, leukocyte and platelet counts are found to be normal. Which of the following is the most likely underlying cause of this disease?

A) Defective globin chain
B) Defective heme synthesis
C) Membrane defect
D) Defective DNA synthesis
E) Hemoglobinopathie
F) Enzyme deficiency
G) Defective DNA repair

19) A 7-month-old male infant is brought to the clinic due to pallor and growth retardation. Physical examination reveals tachycardia and an anomaly of the thumb. Laboratory tests show a hemoglobin level of 4.6 g/dL, hematocrit of 14%, MCV of 108 fl, leukocyte count of 9,000/mm3, platelet count of 360,000/mm3, and reticulocyte count of 0.1%. Vitamin B12 and folate levels are normal, but the patient has decreased serum iron-binding capacity and increased Hb F on hemoglobin electrophoresis. The hand X-ray of the patient is shown below.

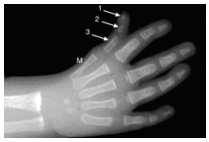

Which of the following laboratory findings would most likely support the diagnosis in this patient?

A) Erythrocyte antigen deficiency
B) Ring sideroblasts in the bone marrow
C) Increased erythrocyte ADA levels
D) Direct Coombs positivity
E) Elevated alpha-fetoprotein levels

20) A 28-year-old man presents to his dermatologist with multiple pigmented skin lesions and a history of basal cell carcinoma. He reports that he has undergone multiple surgical excisions of skin lesions in the past, primarily on his face and upper body. Additionally, he mentions a family history of similar skin findings, with his father and paternal grandmother also having a history of frequent skin surgeries for basal cell carcinoma. On physical examination, the dermatologist notes multiple pigmented nodules and pitted depressions on the patient's face and back. Some of the lesions exhibit telangiectasias, and there are evident signs of surgical scars. Based on the patient's clinical presentation and family history, the dermatologist suspects a hereditary cancer predisposition syndrome and decides to conduct further investigations. Which of the following genetic mutations is most likely to be identified in this patient ?

A) BRCA1 gene mutation
B) APC gene mutation
C) PTCH1 gene mutation
D) TP53 gene mutation
E) MLH1 gene mutation
F) CDKN2A gene mutation

21) A 68-year-old male with a history of chronic atrial fibrillation and previous ischemic stroke presents to the neurology clinic for a follow-up visit. He has been managed on warfarin for anticoagulation and atorvastatin for dyslipidemia. Despite optimal anticoagulation, he continues to experience recurrent transient ischemic attacks characterized by sudden-onset weakness and numbness on the right side of his body, lasting for a few minutes before resolving completely. His physical examination is unremarkable except for a well-controlled blood pressure. Given the recurrence of TIAs despite adequate anticoagulation, the medical team decides to add an antiplatelet medication that works through a different mechanism. They consider using a medication that inhibits phosphodiesterase to increase levels of cyclic nucleotides, leading to vasodilation and inhibition of platelet aggregation. Which of the following medications would be the most suitable option?

A) Clopidogrel
B) Eptifibatide
C) Dipyridamole
D) Rivaroxaban
E) Cilaztazole

22) A 28-year-old male presents to the clinic with complaints of chronic diarrhea and progressive weakness. He reports that these symptoms have been present for several years and have worsened over time. The patient also mentions that he has difficulty seeing at night and that his vision has gradually deteriorated. On physical examination, the patient is noted to have muscle wasting and absent deep tendon reflexes. Laboratory investigations reveal low levels of total cholesterol, triglycerides, and vitamin E. Genetic testing reveals a mutation in the microsomal triglyceride transfer protein gene. Due to the clinical presentation, a bowel biopsy is planned for the patient. Which of the following is most likely to be observed in the biopsy of this patient ?

A) PAS (+) macrophages
B) Lipid vacuoles in epithelial cells
C) Absence of ganglion cells
D) Abnormal apical vesicles
E) Oval ulcers parallel to the lumen

23) A 54-year-old patient diagnosed with scleroderma is referred to a gastroenterologist for chronic diarrhea. In the patient's history, it is revealed that they had previously experienced chronic reflux symptoms and episodes of esophagitis, which improved with lifestyle changes and proton pump inhibitor therapy. The patient denies the presence of blood or mucus in the stool, but reports occasional oily stools without accompanying abdominal pain. Jejunal aspirate culture is suggested as a definitive diagnostic method, but the patient refuses. Therefore, a treatment-to-diagnosis approach is planned, and the patient is started on antibiotics. What is the most appropriate antibiotic to administer to this patient ?

A) Amoxicillin-clavulanic acid
B) Vancomycin
C) Rifaximin
D) Rifampicin
E) Ceftriaxone

24) A 19-year-old male presents to his primary care physician with a complaint of mild jaundice that has been present for several years. He reports occasional episodes of dark urine, but denies any associated abdominal pain, fever, or changes in bowel movements. The patient mentions that his sister also experiences similar symptoms. On physical examination, he has yellowish discoloration of the sclerae but no other abnormalities are noted. Laboratory investigations reveal elevated levels of conjugated bilirubin, with normal liver function tests, including serum alanine aminotransferase and alkaline phosphatase. A liver biopsy is performed, which shows dark brown granules within the hepatocytes. Which of the following best describes the pathophysiology leading to this condition in this patient ?

A) Mildly reduced level of UDP-glucuronosyltransferase activity
B) Deficiency of UDP-glucuronosyltransferase
C) Markedly reduced level of UDP-glucuronosyltransferase activity
D) Impaired biliary excretion of bilirubin glucuronides
E) Defect in the hepatic storage of conjugated bilirubin

25) A 3-month-old male infant presents with a history of recurrent severe bacterial infections. Physical examination reveals delayed separation of the umbilical cord, poor wound healing, and absence of pus formation despite infection. Laboratory studies show marked neutrophilia. Flow cytometry analysis demonstrates a lack of CD18 expression on leukocytes. Which of the following is the most likely defect in this patient ?

A) Failure to detect DNA damage
B) Decreased Th1 response
C) Defective antigen presentation
D) Impaired cell-mediated immunity
E) Microtubule dysfunction
F) Impaired migration and chemotaxis

26) A 38-year-old female with a medical history of stage II breast cancer presents to the oncology clinic for a follow-up visit after receiving her second cycle of chemotherapy, which includes doxorubicin and cyclophosphamide. During the visit, the patient complains of fatigue, weakness, and recurrent episodes of low-grade fever over the past week. Physical examination reveals mild pallor, and there are no signs of active bleeding or hepatosplenomegaly. The patient's complete blood count shows a leukocyte count of 2,000/µL, with an absolute neutrophil count of 700/µL. Hemoglobin and platelet counts are within normal limits. Given the patient's current neutropenic state following chemotherapy and the increased risk of potentially life-threatening infections, the oncologist decides to initiate a pharmacological agent to stimulate neutrophil production. The chosen drug should act through G-CSF receptor stimulation to improve the patient's neutrophil count and decrease the risk of infectious complications. Which of the following medications is most likely to be prescribed to this patient based on its mechanism of action ?

A) Oprelvekin
B) Romiplostim
C) Filgrastim
D) Epoetin alfa
E) Darbepoetin alfa

27) A 12-year-old child is brought to the clinic with complaints of high fever, abdominal pain, and bloody diarrhea. Physical examination reveals a temperature of 39.2 °C, mild signs of dehydration, and increased bowel peristalsis. The complete blood count shows a white blood cell count of 8,000/mm3 (88% neutrophils), and stool examination reveals abundant leukocytes and erythrocytes. A culture of the stool on MacConkey Agar yields the image shown. The isolated bacteria are identified as oxidase-negative, H2S-negative, lactose-negative, non-motile gram-negative bacilli.

Which of the following bacteria is most likely responsible for the findings in this case?

A) Salmonella Enteritidis
B) Shigella flexneri
C) Klebsiella pneumoniae
D) Escherichia coli
E) Proteus vulgaris

28) A 61-year-old male who has been hospitalized in the intensive care unit for five days due to multiple traumas and altered consciousness following a non-vehicular accident is being investigated for deteriorating vital signs and high fever. Serial blood cultures reveal the growth of oxidase-negative, slow lactose-fermenting, DNase-positive, motile gram-negative bacilli. Subcultures on agar plates yield growth similar to the one shown in the image.

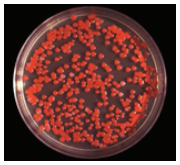

Which of the following bacteria is most likely responsible for the findings in this patient?

A) Salmonella Paratyphi B
B) Klebsiella pneumoniae
C) Pseudomonas aeruginosa
D) Escherichia coli
E) Serratia marcescens

29) A 32-year-old traveler returning from a tropical region presents to the clinic with symptoms of high-grade fever, chills, and fatigue. The patient reports a recent visit to a malaria-endemic area. Upon examination, the patient's blood smear reveals the presence of trophozoite ring within erythrocyte. To treat the patient's disease, the physician decides to initiate a medication that blocks detoxification of heme into hemozoin. However, it is important to consider the stage of the parasite's life cycle that this medication may not effectively target. Which form of the parasite is least susceptible to the action of this medication ?

A) Young rings
B) Mature trophozoites
C) Merozoites
D) Schizonts
E) Gametocytes

30) A 45-year-old woman presents to the rheumatology clinic with a two-year history of progressively worsening symptoms. She complains of Raynaud's phenomenon, which causes her fingers to turn white and blue in response to cold temperatures. Additionally, she has noticed thickening and tightening of the skin on her fingers, which has led to difficulty with grasping objects. On examination, her skin appears tight and shiny, with limited mobility of the fingers. She also has telangiectasias on her face and hands. Pulmonary function tests reveal a restrictive pattern with reduced lung volumes. Laboratory investigations reveal positivity for a spesific antibody for this condition. Which of the following antigens is most likely to be the target of the patient's antibody ?

A) U1 ribonucleoprotein
B) Topoisomerase I
C) Cyclic citrullinated peptide
D) Centromere
E) Cytosolic 5'-nucleotidase
F) Helicase
G) Signal recognition particle

31) A 3.5 kg (7.7 lb), full-term male neonate is delivered via vaginal delivery at a community hospital. During the delivery process, the obstetrician encounters shoulder dystocia and employs excessive traction to deliver the baby's anterior shoulder. A few hours after birth, the neonate's right arm appears limp and adducted at the shoulder, with the elbow extended and the forearm pronated. The neonate exhibits a lack of active movement in the right upper extremity, but there is no gross deformity or bony crepitus. A neurologic examination of the right arm reveals a loss of sensation over the lateral aspect of the right shoulder and a decreased Moro reflex on the right side. There is also muscle weakness involving the right shoulder abduction, elbow flexion, and forearm supination. The left upper extremity and the rest of the neurological examination are unremarkable. Which of the following structures is most likely affected in this neonate ?

A) Axillary nerve
B) Median nerve
C) Radial nerve
D) Ulnar nerve
E) Upper trunk (C5-C6 roots)
F) Lower trunk (C8-T1 roots)

32) A 35-year-old male presents to the dermatology clinic with complaints of an intensely itchy rash on his elbows, knees, and buttocks. Physical examination reveals grouped vesicles and papules with excoriations in these areas. A skin biopsy is performed, and histological examination shows granular deposits of IgA in the dermal papillae. The patient's symptoms, along with the biopsy findings. Further laboratory investigations confirm an association with gluten-sensitive enteropathy. Which of the following is the first-line treatment for this patient's condition ?

A) Topical corticosteroids
B) Systemic corticosteroids
C) Dapsone
D) Oral antihistamines
E) Topical calcineurin Inhibitor
F) Etanercept

33) A 15-year-old patient undergoes surgical resection of a cystic tumor located in the right cerebellar hemisphere. Histological examination reveals a tumor with spindle-shaped cells and a biphasic pattern consisting of variable compact and microcystic areas. Numerous corkscrew eosinophilic bundles are observed within the compact areas. The tumor cells show positive immunoreactivity for glial fibrillary acidic protein.

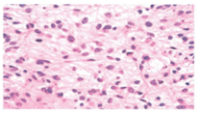

What is the most likely diagnosis in this patient ?

A) Pilocytic astrocytoma
B) Diffuse astrocytoma
C) Anaplastic astrocytoma
D) Glioblastoma
E) Ependymoma

34) A 45-year-old male is brought to the emergency department following a motor vehicle accident. On examination, he is unresponsive with decerebrate posturing, indicating brainstem dysfunction. Further evaluation reveals a dilated left pupil and weakness of the right arm and leg. Non-contrast head CT scan shows a midline shift of the brain structures with the left cingulate gyrus herniating under the falx cerebri. Depending on the patient's condition, which of the following arteries is at risk ?

A) Anterior cerebral artery
B) Middle cerebral artery
C) Posterior cerebral artery
D) Basilar artery
E) Lenticulo-striate artery

35) A 32-year-old male patient with a history of major depressive disorder presents to the psychiatric clinic with ongoing symptoms of low mood, loss of interest, and sleep disturbances. The patient has tried several antidepressant medications in the past, but his symptoms have not responded adequately to treatment. The psychiatrist decides to prescribe a new antidepressant medication with lack of significant reuptake inhibition. Which of the following antidepressant medications is most likely to be prescribed to this patient ?

A) Venlafaxine
B) Clomipramine
C) Protriptyline
D) Milnacipran
E) Mirtazapine

36) A 17-year-old male presents to the clinic with a chief complaint of generalized fatigue, muscle weakness, and recurrent episodes of painful muscle cramps. He also reports occasional episodes of dizziness and palpitations. The patient's medical history is unremarkable, and there is no family history of any significant renal or cardiac conditions. Given the patient's clinical presentation and laboratory findings, a suspicion of an underlying renal tubular disorder arises. Genetic analysis is performed to identify potential mutations associated with tubular defects, and interestingly, a heterozygous mutation in the Na-2Cl-K co-transporter gene expressed in the thick ascending limb of the loop of Henle is detected. Which of the following laboratory findings of this disease is most likely to be expected?

	Potassium	Renin	Aldosteron
A)	High	Low	Low
B)	Low	High	High
C)	Low	Low	High
D)	Low	Low	Low
E)	High	High	High

37) A 55-year-old male with a history of hypertension, type 2 diabetes mellitus, and obesity presents to his primary care physician for a routine check-up. His blood pressure has been difficult to control despite lifestyle modifications and previous treatment with an angiotensin-converting enzyme (ACE) inhibitor. On examination, his blood pressure is 160/100 mmHg, and his BMI is 34 kg/m^2. Laboratory tests reveal elevated fasting blood glucose levels and mild proteinuria. To address his uncontrolled hypertension, the physician decides to initiate a new diuretic, known for its efficacy in reducing blood pressure by promoting diuresis. This diuretic primarily exert their diuretic effect by inhibiting the sodium-chloride symporter. Considering the mechanism of this medication, what is the location where the given medication primarily acts in this patient ?

A) Proximal tubule
B) Proximal tubule and thin descending limb of Henle
C) Thick ascending limb of Henle
D) Distal convoluted tubule
E) Collecting ducts and distal part of the distal tubule

38) A 52-year-old woman presents to her primary care physician with complaints of progressively worsening abdominal pain and distension over the past few months. She also reports unintentional weight loss, fatigue, and occasional episodes of rectal bleeding. On physical examination, a palpable mass is noted in the lower abdomen. Laboratory investigations reveal a mild normocytic anemia. Imaging studies demonstrate a large solid mass arising from the uterus with infiltration into adjacent structures. A biopsy of the mass reveals spindle-shaped cells with elongated nuclei arranged in fascicles. Which of the following is the most likely origin cell for this patient's tumor ?

A) Hepatocyte
B) Adipocyte
C) Endothelial cell
D) Smooth muscle cell
E) Squamous epithelial cell

39) A 51-year-old man presents with symptoms suggestive of renal failure. He reports a decade-long history of nocturia occurring 2-3 times per night, along with recurring bilateral flank pain, notably without associated weight loss. During the examination, his blood pressure measures at 164/100 mmHg, and a deep-seated mass is palpable in the right flank (costovertebral angle). Given these clinical observations, what's the most likely diagnosis for his condition ?

A) Horseshoe kidney
B) Nephrolithiasis
C) Papillary necrosis
D) Polycystic kidney disease
E) Renal cell carcinoma

40) A 22-year-old female patient presents with right upper quadrant pain and jaundice. On physical examination, subicteric sclerae are observed. The Murphy's sign is positive, and the spleen is palpable at 4 cm. Laboratory results reveal a hemoglobin level of 11 g/dL, MCV of 82 fL, MCHC of 39, total bilirubin of 10 mg/dL, direct bilirubin of 8.2 mg/dL, and indirect bilirubin of 1.8 mg/dL. What is the most likely diagnosis in this patient ?

A) Sickle Cell Anemia
B) Thalassemia Major
C) Sideroblastic Anemia
D) Glucose-6-Phosphate Dehydrogenase Deficiency
E) Hereditary Spherocytosis

CEVAP ANAHTARI

1)C
2)E
3)D
4)A
5)B
6)C
7)D
8)C
9)B
10)D
11)B
12)B
13)A
14)D
15)D
16)D
17)B
18)A
19)C
20)C
21)E
22)B
23)C
24)D
25)F
26)C
27)B
28)E
29)E
30)D
31)E
32)C
33)A
34)A
35)E
36)B
37)D
38)D
39)D
40)E